

Percutaneous Endoscopic Gastrostomy in Patients With Complete Dysphagia Due to Neurologic Disorders

Dr. Yusuf BAYRAKTAR , Dr. Tankut KÖSEOĞLU, Dr. Bülent SİVRİ,
Dr. Tülay KANSU, Dr. Burhan KAYHAN, Dr. Kubilay VARLI, Dr. Hasan TELATAR

Özet: NÖROLOJİK HASTALIKLARA BAĞLI KOMP-
LET DİSFAJİSİ OLAN HASTALARDA PERKÜTAN
ENDOSKOPIK GASTROSTOMİ

Perkütan endoskopik gastrostomi (PEG) mutlak yutma güçlüğü olan 15 hastaya yapıldı. İşlem tüm vakalarda başarılı oldu ve hastalar iyi tolere ettiler. Üç hasta halen tüpü kullanmaktadır. 4 hastada yutma güçlüğü kaybolduğu için PEG işleminden 5 ay sonra çıkarıldı. 8 hasta temelde yatan hastalığı nedeniyle öldü. Bu hastalarda tüp ortalama 110 gün kaldı. Bir olguda insizyonel enfeksiyon oluştu başka da işleme ilişkin bir komplikasyon gözlenmedi.

Özetle, PEG cerrahi gastrostomiye alternatif faydalı komplikasyonu az, ucuz bir yöntemdir ve anatomik olarak özefagusu normal yutma güçlüğü olan hastalara yapılmalıdır.

Anahtar Kelimeler: Perkütan endoskopik gastrostomi (PEG), endoskopi, disfaji

Dysphagia is a major complication of stroke and a common problem not only in patients with central nervous system disorder but also in elderly hospitalized patients. These patients are at risk of dehydration, malnutrition and aspiration pneumonia. Naso-gastric tube feeding is commonly undertaken to minimize these risks. Naso-gastric intubation is often distressing for patients, particularly as tube need regular resiting. In a stroke unit, an average of 12 tubes can be used for an intubated patient. It is expensive, uncomfortable and unaesthetic.

Until the beginning of 1980, the only alternative to naso-gastric feeding was surgical intervention, gastrostomy, which requires laparotomy,

Summary: Percutaneous endoscopic gastrostomy (PEG) was performed on 15 patients who were completely dysphagic. The procedure was successful and well tolerated by all patients. Three patients still have had a functioning PEG, the longest one 20 weeks and the shortest one 4 weeks after insertion, in four patients whose swallowing recovered the tube has been removed 5 months after its insertion. Eight patients subsequently died of their underlying disease, a mean of 110 days following PEG. There was an insisional infection only in one case and no other procedure-related complication.

In conclusion, PEG is a useful alternative to surgical gastrostomy in patients with dysphagia who have anatomically normal esophagus.

Key Words: Percutaneous endoscopic gastrostomy (PEG), endoscopy, dysphagia.

general anaesthesia and surgical team. Although gastrostomy under endoscopic control had been first described in 1980 (1), we started to perform the PEG about 10 years later in dysphagic patients. We report our own experience with PEG, carried out in 15 patients over a 14 months period.

MATERIAL and METHODS

We used "pull" PEG tube (Bard interventional Product, Tewksbury, MA) which contains a 60.96 cm feeding tube with a 20 F lumen. Following a complete endoscopic examination including duodenum, stomach and esophagus, the stomach is insufflated to appose the gastric and abdominal walls. After local anaesthetic injection to the best profitable area which is mostly left side of middle line of epigastrium a long

From the Departments of Gastroenterology and Neurology, Hacettepe University School of Medicine, Ankara-TURKEY.

thread is introduced into the stomach under endoscopic observation, via a percutaneous cannula, gripped by a biopsy forceps, pulled out through the patient's mouth and tied to the distal end of the gastrostomy tube. The thread is then used to pull the tube back through the patient's esophagus and stomach and out through the anterior abdominal wall. The intragastric end of the tube is held in place with an integral retention disc which also seals the inner wall of the stomach. A small fixation plate keeps the tube in position on the anterior abdominal wall (Fig. 1-7). All procedures were undertaken in an endoscopy suit room by a team of two physicians (one endoscopist) and one nurse. PEG usually needed additional 15 minutes to the duration of standard upper gastrointestinal tract to complete the procedure. There was no endoscopic difficulty particularly in esophagus during procedure. It should be noted that we needed to pass the endoscope again after the procedure to control the position of the catheter and the passage of tap water by irrigation.

RESULTS

We have performed PEG in 15 patients (9 male, 6 female). Their mean age was 47 years and ranged from 21 to 63. Table I shows the cause of dysphagia (Table I). The interval between the onset of the disease and PEG averaged 40 days and ranged from 25 days to 180 days.

The procedure was successful and well tolerated by all patients. Technical problem was not encountered. No patients had esophageal or gastric lesions. Thus, we did not have difficulty in performing endoscopy. Local infection at the site of tube insertion developed only in one patient, and healed by antibiotic treatment. We did not use prophylactic antibiotics. In one patient we needed to replace the gastrostomy tube because of blockage by crushed drugs.

Following the procedure of PEG, the ability to swallow was regained in four patients, allowing us to remove the tubes a mean duration of 4 months after their insertion. These patients are doing well. Of the remaining 11 patients, 3 still have their tubes in situ, a median duration of 13 weeks after the insertion. Tubes have been in

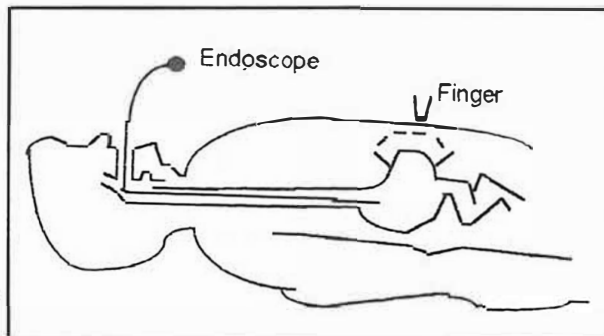


Fig 1: An endoscope insufflate the stomach.

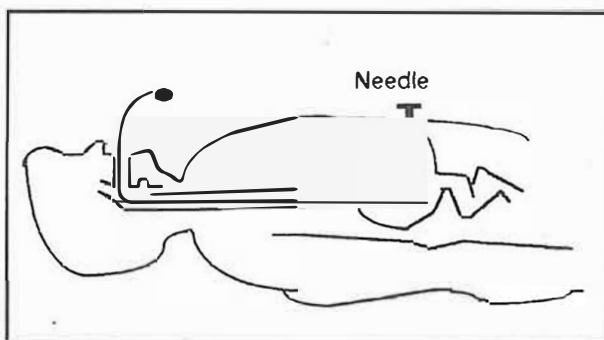


Fig 2: 25 Gauge needle enters the stomach.

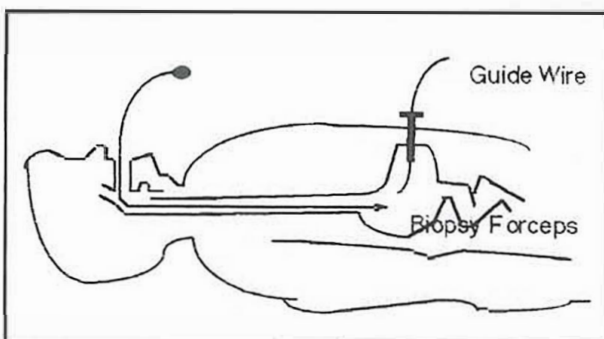


Fig 3: A biopsy forceps is grasped the wire.

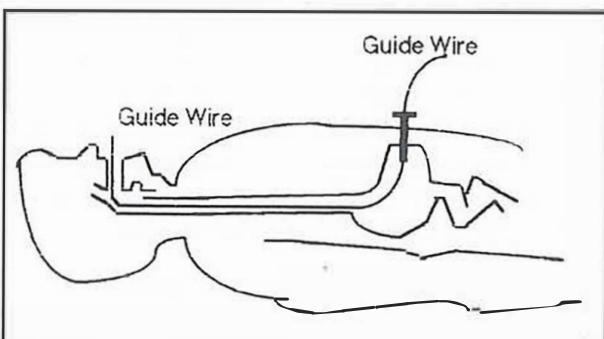


Fig 4: The wire is pulled out.

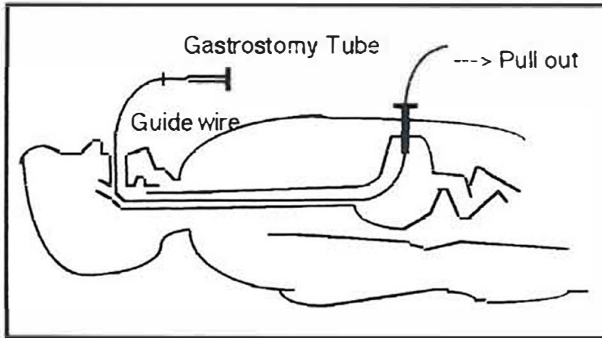


Fig 5: The tube is secured extraorally to the wire.

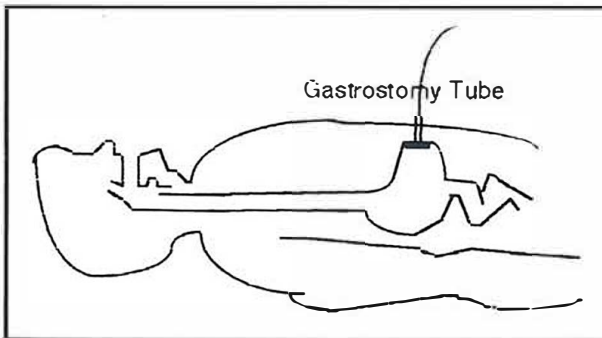


Fig 6: The wire and the tube are repulled out.

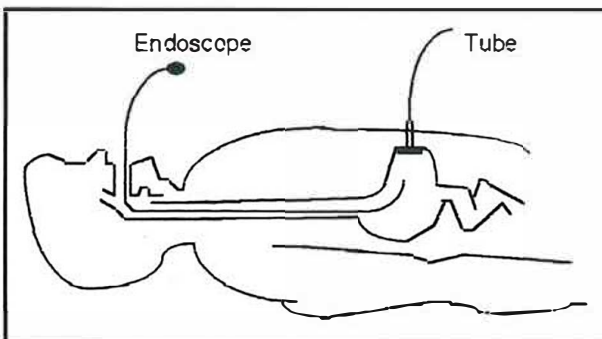


Fig 7: The endoscope controls the position of the tube.

situ for longer than one month in 13 patients and longer than six months in three patients. Eight patients died of causes unrelated to the procedure. Four of them because of pulmonary disease, as a complication of myasthenia gravis developed before the procedure, and the remaining 4 patients died of underlying disease.

Fortunately, no patient developed peritonitis or other complications such as perforation of the colon and bleeding which are the common complication in large series.

Tablo I: Underlying diseases in 15 patients with dysphagia.

Underlying Disease	No. of Patients
Cerebro vascular accident	8/15
Myasthenia gravis	5/15
Bulbar palsy	1/15
Encephalitis	1/15
Total	15

DISCUSSION

Naso-gastric intubation are the common practice in patients admitted to the hospital because of various central nervous system disorders causing dysphagia such as cerebrovascular accidents, severe trauma and myasthenia gravis. When they are needed for extended periods, not only naso-gastric tubes tend to become dislodged and needs to be resited but also all medical treatments were tended to be used parenterally which is expensive and potentially harmful. Like others (2-4), dissatisfaction with nasogastric intubation prompted us to use alternative feeding strategies which are very popular in some countries but very rare in Turkey. In fact this series is too small, but is the first and largest series in our country. To popularize this procedure, we attempted to PEG because of its reported simplicity, feasibility and low complication rate (5-6). The enteral route is the preferred method of nutrition in patients with a functional gastrointestinal tract. To provide enteral feeding, PEG is the best way. Unlike surgical gastrostomy, there is no need for general anaesthesia, and laparotomy which can be intolerable procedure in a patient with neurologic problem. But upper gastrointestinal endoscopy is tolerated well not only in elderly patients but also patients with nervous system problem and we have found that the same applies to PEG. It was successful in all our patients. In four patients with myasthenia gravis complicated with aspiration pneumonia before procedure, we encountered some difficulties due to respiratory distress during endoscopy. In some studies, the success rate varied from 76% to 99% (6-7), with rates of greater than 90% in the majority. In a recent review of more than 200 reported PEGs, the incidence of major complication varied from 0% to 4%; the mortality

rate ranged from 0% to 2.5% (4). One patient in our series had insicional infection responding to antibiotic therapy and, one patient needed the tube to be replaced because of blockage of the lumen. Late mortality following PEG does not reflect always technical success but reflects patient selection. In our series, no patient died of as a consequence of the procedure, 8 patients have subsequently died. The interval between PEG and death averaged 110 days and the 30 days mortality rate was 6% (one case), the reason for death was underlying disease and its complication such as pulmonary infection. At the beginning, we encountered the resistance of doctors who are responsible for the patients' care. We agree with the suggestion of performing PEG earlier in a patient's course which might improve

nutritional status and thereby reduce the early death rate (4).

During this procedure, it is also possible to detect whether the patients have any upper gastrointestinal lesions such as peptic ulcer which is a contraindication for the use of steroids and gastric cancer which is common in elderly patients. After dissolving the acute neurologic problems, the patients can be discharged and this feeding tube can easily be used at home.

The procedure is now well established and in our opinion is of considerable benefit to patients with dysphagia due to neurologic disorders. It is an effective method to minimize the dissatisfaction of naogastric tube, easily performed and have no serious complications.

KAYNAKLAR

1. Gauderer M.W.L., Ponsky, J.L. & Izant R.J. Gastrostomy without laparotomy: a percutaneous endoscopic technique. *J pediatr surgery* 1980, 15: 872-875.
2. Mamel, J.J. Percutaneous endoscopic gastronomy. *Am J Gastroenterol* 1989, 84: 703-710.
3. Ponsky, J.L. & Gauderer, M.W.L. Percutaneous endoscopic gastrostomy: Indications, limitations, techniques and results. *World J Surg* 1989, 13: 165-170.
4. Miller, R.E., Castlemain, B., Lacqua, F.J. & Kotler, D.P. Percutaneous endoscopic gastrostomy. Results in 316 patients and review of literature. *Surg Endosc* 1989, 3: 186-190.
5. Larson, D.E., Barton, D.D., Schroeder, K.W. & Dimagno, E.P. Percutaneous Endoscopic gastrostomy: Indication, success, complications and mortality in 314 consecutive patients. *Gastroenterology* 1987, 93: 48-52.
6. Thatcher, B. S., Ferguson, D.R. & Paradis, K. Percutaneous endoscopic gastrostomy: A preferred method of feeding tube gastrostomy. *Am J Gastroenterol* 1984, 79: 748-750
7. Sangster, W., Cuddington G.D. & Bachulis B.L. Percutaneous endoscopic gastrostomy. *Am J Surg* 1988, 155: 677-679.